

# EMDR and Phantom Limb Pain

---

## Theoretical Implications, Case Study, and Treatment Guidelines

**Jens Schneider**

*Clinic for Internal and Psychosomatic Medicine, Bad Fredeburg, Germany*

**Arne Hofmann**

*EMDR-Institute Deutschland, Bergisch Gladbach, Germany*

**Christine Rost**

*Frankfurt Center for Psychotraumatology, Frankfurt, Germany*

**Francine Shapiro**

*Mental Research Institute, Palo Alto, California*

This article reviews the literature on EMDR treatment of somatic complaints and describes the application of Shapiro's Adaptive Information Processing (AIP) model in the treatment of phantom limb pain. The case study explores the use of EMDR with a 38-year-old man experiencing severe phantom limb pain 3 years after the loss of his leg and part of his pelvis in an accident. Despite treatment at several rehabilitation and pain centers during the 3 years, and the use of opiate medication, he continued to experience persistent pain. After 9 EMDR treatment sessions, the patient's phantom limb pain was completely ablated, and he was taken off medication. Effects were maintained at 18-month follow-up. The clinical implications of this application of EMDR are explored.

**Keywords:** phantom limb; pain; EMDR; adaptive information processing

**A**ccording to the Amputee Coalition of America, there are approximately 1.6 million Americans in the United States currently living with limb loss. While figures are hard to come by internationally, this frequency is probably representative of other developed countries. Added to this are reports from the World Health Organization indicating that 15,000–25,000 persons are killed or maimed annually by land mines in developing nations; 80% of these victims are civilians, the majority children, and one third of the survivors require amputation (Walsh, 2003). As with all amputees, chronic pain is often a factor in any attempts at rehabilitation (De Smet, Charlton, & Meynadier, 2000).

According to some estimates, phantom limb sensations are experienced by as many as 80% of amputees (Melzack, 1992). Although the illusion that the limb is present may have beneficial effects, such

as facilitating the use of new leg prostheses, it is reported to be accompanied, in more than half of the cases, by excruciating and chronic pain (Flor, 2002a; Koojiman, Dijkstra, Geertzen, Elzinger, & van der Shan, 2000).

### The Treatment of Phantom Limb Pain

Unfortunately, the ability of clinicians to effectively treat phantom limb pain is thwarted by a dearth of controlled research (Halbert, Crotty, & Cameron, 2002). For the most part, they must rely on the results of individual case studies, which have reported some positive effects for relaxation therapy (McKechnie, 1975), biofeedback (Tsushima, 1982), and hypnosis (Wain, 1986). Additional refinements of biofeedback treatment involving limb temperature appear to have some salutary effects with subsets of

patients experiencing certain types of pain (Sherman, Arena, Griffin, Bruno, & Cocilovo, 1991). However, none of the treatments have been widely supported by systematic, controlled research.

Traditional treatments for phantom limb pain have concentrated on the presumed transmission of pain stimuli from peripheral loci to the brain, for example, by severing certain spinal cord nerves (e.g., Flor, 2002a). Unfortunately, even the best effects of these interventions were typically reported by patients to be both inadequate and short lived. Indeed, in some cases, they did not even exceed those of the placebo control condition (Sherman, 1997; Sherman, Ernst, Barja, & Bruno, 1988). In contrast to earlier treatments, recent models of phantom limb pain have emphasized events taking place in the brain, such as cortical reorganization (Bierbaumer, Lutzenberger, Montoya, & Larbig, 1997; Flor 2002b, 2004; Karl, Muehlnickel, Kurth, & Flor, 2004). This conceptualization of the concomitants of the malady has led to an array of new interventions, which include electrical prostheses (Lotze, Flor, Grodd, Larbig, & Birbaumer, 2001), mirror boxes (McCabe et al., 2003; Ramachandran, & Rogers-Ramachandran, 1996), sensory stimulation (Flor, Denke, Schaefer, & Grusser, 2001), and visuomotor training (Giroux & Sirigu, 2003). These procedures, while promising, have not been systematically tested by controlled, replicable research.

Another conceptualization of chronic pain emphasizes the role of emotion as a central factor in the production and maintenance of pain (e.g., Melzack, 1996; Price, 1999; Rome & Rome, 1999). As elaborated by Ray and Zbik (2001), previous models of the management of pain (phantom or real) do not sufficiently take into account the affective element of the pain sensation. They argue that chronic pain can perhaps best be understood as an interaction of physical and psychological factors and recommend that treatment should address the emotional components of pain. According to these authors, while cognitive behavioral therapy (CBT) is effective in reducing pain, eye movement desensitization and reprocessing (EMDR) is superior. Specifically, CBT introduces techniques to allow the patients to alter their thoughts or physical reactions to the pain sensations, while EMDR treatment “not only works through cognitions, but also seems to have a direct effect on desensitizing the limbically augmented portion of the pain experience. . . In this way, EMDR adds a dimension to the treatment of pain that is quite different from cognitive and/or behavioral interventions, including hypnosis (Ray and Zbik, 2001, pp. 205–206).”

## Phantom Limb Pain From an Adaptive Information Processing Model Perspective

EMDR is informed by the AIP (Shapiro, 2001, 2002) model, which posits that when distressing memories are stored in isolation and inadequately processed, the dysfunctional emotions, perspectives, and sensations of the initial event are essentially unchanged. The model views chronic pain as involving not only the automatic emotional response to the pain sensation, but also the somatic component of the stored memories. Accordingly, EMDR treatment of chronic pain, including phantom limb pain, includes the processing of both the associated disturbing affective responses and the memories of pain-related etiological events (Shapiro, 1995, 2001, 2002; Shapiro & Forrest, 1997; see also Christman, Garvey, Propper, & Phaneuf, 2003; Siegel, 2002; Stickgold, 2002; van der Kolk, 2002). As noted by Ray and Zbik (2001), recent brain research demonstrates that “there are now neurochemical explanations, i.e., kindling, neuroplasticity, limbically augmented pain syndrome, etc., that can properly account for the patient’s degree of suffering” (p. 203); these explanations, they state, are congruent with Shapiro’s AIP model.

## Description of EMDR Treatment

The primary goal of EMDR treatment is to gain access and process stored memories by means of a set of standardized procedures, which include repetitive eye movements, auditory signals, or tactile stimulation. Eye movements have been shown in controlled studies to reduce affect and to increase attentional flexibility and the retrieval of episodic memory (e.g., Andrade, Kavanagh, & Baddeley, 1997; Barrowcliff, Gray, Freeman, & MacCulloch, 2004; Christman, Garvey, Propper, & Phaneuf, 2004; Kuiken, Bears, Miall, & Smith, 2001–2002; Van den Hout, Muris, Salemink, & Kindt, 2001). EMDR includes an association process that may further serve to facilitate transformation of the target memory (see Rogers & Silver, 2002; Shapiro, 1995, 2001, 2002; Stickgold, 2002) and its integration within relevant contextual memory networks.

EMDR is an integrative psychotherapy approach consisting of eight phases and specific protocols used to address the presenting complaints (for details, see Shapiro, 2001). The first phase is Client History, evaluating the entire clinical picture to identify the experiences that will need to be processed to both eliminate the dysfunctional cognitive, emotional, somatic, and behavioral elements and incorporate the positive experiences necessary for a successful future.

The Preparation Phase educates the client about the symptom picture and teaches a range of metaphors and self-control techniques to assist stabilization and facilitate processing. The Assessment Phase accesses the target memory and identifies the image, currently held negative belief, emotion, and physical sensations attendant to the disturbing experience. It also specifies the current rating of distress, using the 0–10 (0 = neutral to 10 = the worst disturbance imaginable) Subjective Units of Disturbance (SUD) scale (Shapiro, 1989; Wolpe 1958), and strength of the desired positive belief, using the 1–7 (1 = completely false to 7 = completely true) Validity of Cognition scale (VOC; Shapiro, 1989, 2001). The reprocessing phases (Desensitization, Installation, and Body Scan) utilize standardized procedures, which include bilateral stimulation (e.g., eye movement, taps, tones) to process the target. During the reprocessing phases, an association process is encouraged, which elicits other experiences contributing to the dysfunction, along with insights and shifts in affective and somatic manifestation. The Closure and Reevaluation phases return the client to equilibrium, self-monitor mid-session distress, and ensure that positive treatment effects have been maintained. The standardized protocols for addressing posttraumatic stress disorder (PTSD) and chronic pain both include the targeting of past events that set the groundwork for the pathology, present triggers that elicit disturbance, and positive templates for appropriate future action.

## **EMDR: An Efficacious Treatment for PTSD**

EMDR was originated by Shapiro (1989, 1995, 2001, 2002) for use with individuals who had experienced severe traumatic stress (e.g., PTSD). Subsequent to numerous controlled studies (e.g., Ironson, Freund, Strauss, & Williams, 2002; Lee, Gavriel, Drummond, Richards, & Greenwald, 2002; Power et al., 2002; see Bradley, Greene, Russ, Dutra, & Westen, 2005; Maxfield & Hyer, 2002), EMDR has become a widely accepted treatment for psychological trauma. In the United States, EMDR has been recommended as a preferred treatment, with the highest level of empirical support and clinical effectiveness, by the American Psychiatric Association (2004) and Department of Veterans Affairs/Department of Defense (2004) practice guidelines. The same is true throughout Europe (e.g., CREST, 2003; Dutch National Steering Committee, 2003; INSERM, 2004; National Institute of Clinical Excellence, 2005) and Israel (Bleich, Kotler, Kutz, & Shalev, 2002), where EMDR has been recommended as a treatment for terrorist victims.

Neurobiological studies have shown EMDR to have significant effects on brain activation patterns subsequent to treatment (Lamprecht et al., 2004; Lansing, Amen, Hanks, & Rudy, in press; Levin, Lazrove, & van der Kolk, 1999; Oh & Choi, 2004), including an increase in hippocampal volume (Bossini, Fagiolini, & Castrogiovanni, in press).

## **EMDR Treatment of Somatic Complaints**

Although there have been no controlled studies investigating EMDR treatment of somatic complaints, there have been a number of published case studies. Additionally, some controlled studies of EMDR treatment of PTSD have reported changes in somatosensory domains (e.g., Carlson, Chemtob, Rusnak, Hedlund, & Muraoka, 1998; Chemtob, Nakashima, & Carlson, 2002; Marcus, Marquis, & Sakai, 1997, 2004; Shapiro, 1989; Wilson, Becker, & Tinker, 1995, 1997; van der Kolk et al., 2007).

One of the participants in the first controlled study (Shapiro, 1989) experienced the complete elimination of what appeared to be the stored somatic memory of oral rape and its debilitating effects. The participant indicated at follow-up that the gagging sensations that had occurred several times a week for 40 years had ceased subsequent to treatment. Another participant in the same study reported that daily headaches had ceased immediately following treatment.

One of the first independent case reports treating a PTSD patient with a persistent somatic component (McCann, 1992) emphasized the multidimensional changes resulting from EMDR. Independent observation corroborated the return to active functioning of a double amputee, including the complete elimination of burning sensations that had been caused by an industrial explosion 8 years previously. Due to emotional and physical disability, he had required 24-hr nursing care since the accident. The EMDR treatment targeted the memory of the accident, with a reliving of the somatic experience of the explosion. Processing elicited associations regarding another near-death experience and a spontaneous expression of spiritual and personal values. Subsequently, the patient reported “that he had heard enough of ‘you’ll never be able to function normally’ and expressed the idea that there was now no limit on what he would be able to do for himself” (p. 322). This case illustrates how the patient’s own cognitive, emotional, and somatic associations during EMDR can lead to an accelerated learning experience that results in both a remediation of symptoms and an enhanced sense of self-efficacy (for detailed transcripts see Shapiro & Forrest, 1997).

## EMDR Studies on Phantom Limb Pain

The first published case of phantom pain eliminated through EMDR involved a Colombian child treated in 1996 for a limb amputation subsequent to a cancer diagnosis (Shapiro & Forrest, 1997). The processing of the pain sensations, together with associated feelings of fear and abandonment at having been left in an agency's care by her family, and dread of "never running and jumping with children again," resulted in a complete elimination of the phantom leg pain, which was maintained at 2 year follow-up. Inspired by these results, other investigators evaluated sequential cases of EMDR application reporting a decrease or remission of phantom pain in 7 of 10 patients (Tinker, Wilson, & Becker, 1997). The current case report is one of a series of patient evaluations presently being conducted in Germany. It is one of the most complex of those reported in published case series (Schneider, Hofmann, Rost, & Shapiro, in press) and has been chosen for this article to explore the range of treatment options and theoretical implications.

### Case Report

This case study details the comprehensive EMDR treatment regime inaugurated with a 38-year-old man (referred to here as "Tom") who was experiencing severe and chronic phantom limb pain since losing his leg and part of his pelvis in a motorcycle accident 3 years previously. Despite a series of pain and rehabilitation treatments, including various medications, over a 3-year period subsequent to the accident, the patient continued to experience persistent phantom limb pain. The patient's physical debilitation from the phantom limb pain and posttraumatic stress consequent to the accident proved to be only part of the clinical picture necessitating treatment. Also of note is the assault on his sense of self-worth and self-efficacy caused by the loss of the leg, compounded by feelings of guilt and sorrow because of the miscarriage his wife suffered due to her own traumatization subsequent to his accident. EMDR was used to address all aspects of the clinical picture.

### Presenting Complaints

Tom experienced severe, unremitting phantom limb pain from his lost right leg, despite taking 600 mg of morphine sulfate (plus 12 other medications) daily. To identify pain level, a standard Visual Analog Scale (VAS; "pain slider"/FACES scale) was used. The patient designates the level of pain along a continuum anchored by a smiling face (no pain) to a crying face (unbearable pain). The clinician can then identify the

numeric equivalent as it is translated on the reverse side from 0 (no pain) to 10 (unbearable pain) in increments of 0.5. Using the scale, Tom indicated that his pain during the day was 6 and rose to 10 at night. Tom's reports of his pain sensations at the time of admission included "it feels like a crushing blow," and "my leg is torn to pieces." These descriptions also articulated key elements of the accident. Additional portrayals of his pain in isolation included "dull," "burning," and "pressing."

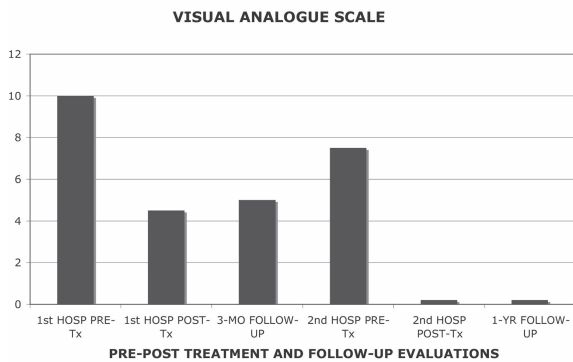
### History

Tom is a 38-year-old chemical worker who is married, with two children. In 1999, at the age of 32, he had a severe motorcycle accident in which he collided with a car. His right leg was disarticulated at the pelvis, and he suffered severe injuries to his rectum, genitals, bladder, hands, and forearms. During his lengthy hospital stay, he lost his right leg, received an anus praeter (an artificial exit of his bowel), and underwent several surgical interventions for his injured bladder and rectum. An attempt to give Tom a prosthetic leg failed because of extensive pain experienced by the patient. Efforts were finally ceased with the conclusion that it would be impossible for anatomical reasons. Tom was subsequently treated for persistent and severe phantom limb pain at several rehabilitation and pain centers, without major success.

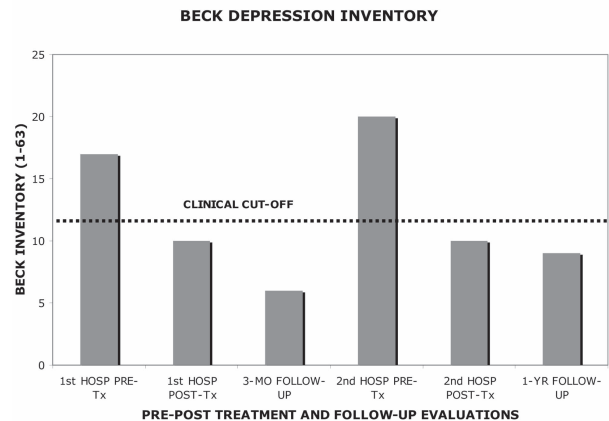
### Assessment

At the time treatment was inaugurated, Tom was assessed with the Structured Clinical Interview (SCID) for the American Psychiatric Association's *Diagnostic and Statistical Manual of Mental Disorders (DSM-IV*; Wittchen, Zauderk, & Fydich, 1997) and it was determined that his symptom profile met diagnostic criteria for PTSD and major depressive disorder. Figures 1–3 indicate the pain levels and scores on the standardized self-report measures that were used to assess Tom's clinical progress during and following treatment. His score (61 out of 75) on the Impact of Event Scale (IES; Horowitz, Wilmer, & Alvarez, 1979) indicated a severe level of trauma symptoms (a score below 20 is considered mild/subclinical). On the Beck Depression Scale (BDI; Beck, Ward, Mendelsohn, Mock, & Erbaugh, 1961; Hautzinger, Bailer, Worall, & Keller, 1992), Tom's score (17 out of 63) was indicative of mild depression (a score below 12 is considered normal). His phantom limb pain level was tracked by means of the VAS.

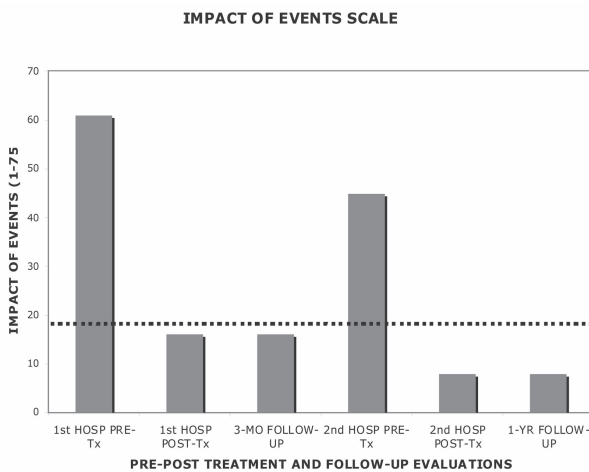
In summary, Tom's life-threatening motorcycle accident left him with an anus praeter; a right leg amputated to the pelvis; a high level of various ongoing medications; severe, resistant phantom limb



**FIGURE 1.** Pre-post and follow-up visual analogue scale.



**FIGURE 3.** Pre-post and follow-up BDI Scores.



**FIGURE 2.** Pre-post and follow-up impact of events scale scores.

pain; depressive symptoms; and serious symptoms of PTSD. Finally, his high levels of medication resulted in lack of concentration and chronic fatigue.

### Case Conceptualization

EMDR treatment is conceptualized according to the AIP model (Shapiro, 2001, 2002). The model posits that while a Criterion A (major trauma) event is necessary for the diagnosis of PTSD, most pathological disorders involve experiential concomitants as well. Their persistent negative effects are attributable, at least in part, to inappropriate storage in memory. It has been conjectured that this dysfunctional storage involves both implicit (Siegel, 2002; van der Kolk, 2002) and episodic memories (Stickgold, 2002). The AIP model assumes that the processing of these events has the effect of integrating the problematic memory with the larger, nondysfunctional memory networks, thereby facilitating the patient's sense of

self-efficacy and ameliorating the overt symptoms. These applications of EMDR have been evaluated by many clinical case studies (see Shapiro 1995, 2001, 2002), which cite reports of the rapid relief from physical problems and somatoform disorders including chronic pain (Brown, McGoldrick, & Buchanan, 1997; Dziegielewski & Wolfe, 2000; Grant, 2000; Grant & Threlfo, 2002; Gupta & Gupta, 2002; Ray & Zbik, 2001; Schneider et al., in press). Most recently, a decrease of deviant arousal and change in attribution in child molesters also has been reported subsequent to the processing of the memory of the offenders' own victimization (Ricci, Clayton, & Shapiro, 2006). The shift in both the perceptual and somatic elements in these clinical populations following EMDR treatment is consistent with the AIP model, which posits that both these elements are inherent within the unprocessed stored etiological memory.

The comprehensive EMDR treatment of Tom's clinical complaints included processing memories and current triggers that contributed to the PTSD, depression, and phantom limb pain, as well as strengthening the positive resources he would need to adjust to life with permanent physical disabilities. It should be emphasized that clinical treatments addressing patients with chronic pain must address both the somatic elements and the sense of identity and self-efficacy that may be undercut by the physical limitation.

### Course of Treatment and Assessment of Progress

**First Hospital Stay (EMDR Sessions 1–7).** Tom participated in 7 weekly EMDR sessions during his inpatient treatment at a specialized hospital. The first session included the Preparation Phase and started with the strengthening of some important emotional resources

through a combination of imagery and bilateral stimulation. The first resource was his physical strength, and the second was the love, security, and understanding of his wife and his children. Tom thought of memories associated with these resources and focused on them while engaging in bilateral stimulation. The emphasis on positive states is consistent with the use of EMDR for the activation of resources in patients with compromised affect tolerance (Korn & Leeds, 2002). The Preparation Phase increases the patient's access to positive memories and affects if needed during subsequent processing.

At the next meeting, the first author initiated the EMDR standard protocol for treating traumatic memories (Shapiro 1995, 2001). This was the first of 6 processing sessions directed at various memories associated with Tom's condition, as well as the phantom limb pain itself. Table 1 charts the session-by-session course of Tom's progress, including changes in medication levels, beginning with the initial intake.

The worst part of the memory for Tom was the moment of the impact, especially his sensory impression of the crash. His somatic memories were of incredible pain, with all of the symptoms of physical stress. He thought, "I am going to die." His positive cognition was "I survived," with a VOC score of 2-3 (relative low validity). As he thought about the accident, he identified emotions of fear, anxiety, and helplessness. His SUD score was a 10 plus. Tom's initial treatment target was the image of the moment of the crash and the intense pain that felt like his leg was being pulled off. Over the course of 10 sets of eye movements, the pain slowly decreased. After another set, the image switched to a time during his hospital stay when a nurse had accidentally dropped him, causing him to fall on his injured pelvis and producing intense pain. An intense wave of anger came over him that was processed with the eye movements.

Other memories that emerged during the EMDR processing session included his feelings of helplessness and of not knowing what had happened, his inability to move, and his thought that he could not control his current situation because of the debilitating effects of his high medication. During the sets of eye movements, Tom felt the intense emotions of desperation, sadness, grief, and hatred. He moaned and felt pain sensations in his amputated leg, wincing so intensely that he could hardly bear to sit on a chair. This first session came to an end with the emerging thought, "I survived," which countered his strong belief at the moment of the crash that he was going to die. He was glad that he still had the opportunity to create a future with his family. Asked how intense his emotional discomfort was at the end of the session he said 5 (out of 10).

At the beginning of the second reprocessing session, during a review of the previous week, Tom reported that new memories (of his hospital time after the accident) had come up, as well as memories of nightmares he had experienced in the intensive care unit while unconscious in an induced artificial coma under high medication directly following the accident. (This is a medical intervention undertaken in an intensive care unit if victims with severe injuries need time to heal their somatic injuries but are still in intense distress.) Therefore, the target of the next EMDR session was Tom's nightmares while in the coma. His SUD score about these memories was "more than 10." Some of Tom's impressions that emerged during his work on this memory included "each part of my body is going to become amputated" and "my life is just depending on the machines." As this memory was reprocessed, he began spontaneously to recognize new aspects of the experience: "the procedure was necessary to save my life" and the machine stabilized my cardiovascular system."

During the session, Tom also recalled and began to process and differentiate the various dimensions and qualities of pain from each of the medical procedures he underwent, such as the pain originating from the infected urinary bladder versus the abdominal pain caused by the injury to the colon. Each of these special qualities of pain corresponded to the unique memory of the situation when Tom felt that pain for the very first time.

After working through these associations following the standard EMDR procedure, Tom could better acknowledge, step-by-step, his strength and persistence. He recognized that his body was still functioning with a lot of "positive life patterns" that strengthened his confidence in the future. He also realized during this processing session that he had reexperienced and dealt with some qualities of pain that he had not sensed since being discharged from his first hospitalization, 3 years earlier. These observations strengthened his self-confidence in coping with his pain. His SUD score decreased from above 10 to 6. During the following days, he reported that he had gone as much as 4 hr without pain, and that the intensity of the heaviest pain had decreased from a 10 to 7 on the VAS. He was also able to successfully reduce his pain medication by 50%. For example, he lowered his Metamizol medication (an analgesic of medium strength) from 2 g per day to 1 g per day.

Tom's third EMDR processing session was dominated by experiences of loss. He focused on the moment in the hospital when he became aware that he had lost his right leg. No one had told him this during his first 3 weeks at the hospital. His negative thought was: "I am damaged forever." During processing, Tom

**TABLE 1. Treatment Effects and Medication Over Sessions**

Session	Aug 2002 (intake)	1	2	3	4	5	6	December 2002 (outpatient)	February 2003 (outpatient)	7	8	9
Target(s) reprocessed		Traffic accident	Nightmares during artificial coma	Loss of leg and wife's miscarriage	Visit of priest	Medical problems and treatments	Present and future social issues			Photos and reports of crash	Photos and reports of crash	Worst memories
SUD of Event (0-10) Pre-session	10	10+	10+	7	5	6	3	NA	10	7	6	2
Post-session		5	6	4.5	3	3	1			6	2	0-0.5
<i>In week following session:</i>												
Pain:	10+	7.5	7	5.5	4.5	-4	4	4.5	10	7.5	NA	0
VAS (0-10) for maximum PLP												
Pain: PLP-free hours	No pain free time	No pain free time	4 hrs	NA	Two days	Three days	More than three days	Long pain free times	Extensive times	NA	NA	Completely free
Morphine sulfate	600 mg/day	600 mg/day	600 mg	400 mg	300 mg	300 mg/day	200 mg/day	100 mg/day	300 mg/day on demand	100 mg/day on demand	100 mg/day on demand	100 mg/day on demand
Metamizol	2 g/d	2 g/d	1 g/d	0.5-1 g	0.5-1 g	500 mg on demand	0	0	0	0	0	0
Gabapentin	1800 mg/d	900 mg/d	900 mg/d	900 mg	600 mg	600 mg	0	0	0	0	0	0

*Note.* Pre = before processing; Post = after processing; NA = Not asked; Metamizol = COX-1 inhibiting non-steroidal anti-inflammatory drug (NSAID), used in severe pain cases.

returned to the moment of his accident. The sounds and images of the crash very vividly reemerged. Tom reexperienced the moment when he recognized he was not dead but had lost his leg. He also realized during the processing how much he had relied on his functioning body. He remembered a series of events that demonstrated his struggle for survival, which was accompanied by intense feelings of pain, desperation, horror, and his overwhelming fear of death.

As he focused on the moment, he felt his leg being pulled out of his body. Tom felt again the incredible pain. He cried and displayed all the symptoms of intense physical stress. After six sets of 50 eye movements each, Tom was still stuck in the unchanging awful memory of the crash. As changing the direction of the eye movements was not productive, the therapist (J. S.) therefore decided to introduce an EMDR procedure known as a “cognitive interweave” (see Shapiro, 2001), which elicits through questioning potentially useful adaptive information. The therapist’s creative use of the procedure involved asking him: “What could help you best now to restore your image of the abilities of your body?” Tom then described an image of a warm, complete, and healthy leg. He was asked, “As you think of this image, where do you feel the strength in your body?” He answered: “In my leg” and was asked to focus on this image and the body feeling while simultaneously following the eye movements. The feeling of strength increased during the short set of eye movements and after another set expanded to the pelvis. At the end of these sets, Tom came up with the idea that he could learn to walk with a prosthesis or something similar to this (e.g., walk on crutches). At this point, he became calmer, and his pain decreased. He remembered times when he had gone on wonderful walks with his family and that this would be still possible because he was alive.

During the next eye movement sets, thinking about his family activated a different traumatic event, his wife’s miscarriage of their third child, which was induced by her shock at Tom’s accident. Tom experienced a fit of rage and hatred, and his pain increased and spread all over his body. After four more sets of eye movements, he had a new thought about this miscarriage. Whereas previously he had been sure he was impotent as a result of the accident, he remembered that recent results of a medical test had shown that he was still able to father a child. With that realization, Tom felt more comfortable, because he could reconstruct his self-esteem as a functioning man in his role as a complete husband and father.

After this session, Tom’s SUD score had gone down to 4.5. He continued to have some periods

free of pain, and his medication was further reduced. Between sessions, Tom lost more of his memory gaps and recalled that he had suffered a pulmonary embolism in the hospital after the accident, and that at that time he again had been in critical condition.

The topic of the fourth reprocessing session was the visit of a priest during Tom’s initial stay at the hospital, during which they discussed that God always watches what is happening and will protect everyone. He felt that he not been taken seriously by the priest. The SUD score for this event was 5. Reprocessing the event, Tom reexperienced strong emotions of anger, fury, and guilt. His thought was “I’m not good enough to be protected by God.” Then he remembered that after the visit of the priest he had felt the phantom limb pain for the first time. During the ongoing processing, Tom worked through a number of his life events, experiencing emotions of shame, disappointment, helplessness, and anxiety.

At the end of this session, Tom realized that he had done nothing in his life to deserve punishment, and that the accident had been caused by a drunken driver. His conclusion was that he should invest his energy in building up a new life. He came up with a new positive thought: “If I want, I can be successful.” He then focused on the image of a healthy leg, the image he had found in the last session to symbolize his power for a future life. At the end of this session, his SUD score had gone down to 3. The pain medication (gabapentin and morphine sulfate) was further reduced (see Table 1).

During the fifth reprocessing session, Tom focused on some medical procedures that had occurred during his first months of hospitalization. This included the operation on his hands, the operation on his bowel, treatment for acute kidney failure, and the removal of bladder stones that he had acquired during his hospital stay. These all lost their initial painfulness during the eye movements.

During the last session of this hospital stay, Tom focused on his present and future social abilities and problems. He noticed that many things he had done in former times were still possible, although much more difficult; his family was not disgusted by his appearance; and his economic situation was secure. Tom’s subjective stress level after these 7 sessions (1 preparation and 6 processing) significantly decreased. The SUD for the memory of his accident had decreased to a 1, which appeared ecologically linked to his sorrow about the event. He was now free of pain for up to 3 consecutive days plus additional times during the rest of the week. In addition to these total cessations, at other times the pain was bearable, with peaks of 4 (of 10), at which time he used his “antidote,” the image of the healthy leg that

he had associated with his positive sense of self and ability to survive. He called up the image and focused on it while concentrating on the positive body feeling associated with it. He used this technique every evening before he went to sleep and usually slept well. Another time that he used the image was when he sensed the pain coming on again (which rarely happened now). Thereafter, medication was reduced to the level needed only to control the pelvic pain caused for organic reasons. Tom left the hospital taking 4 pills (including 200 mg morphine sulfate), as compared with the 18 pills that he required on admittance to the clinic.

As noted in Figure 2, at the time of discharge, Tom's IES score was 16, which is considered mild/subclinical, and the BDI (10) was at a normal level. Further treatment was organized on an outpatient basis, with a frequency of one consultation per month and telephone calls at regular intervals. Three outpatient follow-up contacts with Tom indicated maintenance of treatment effects. He was formally tested once following his treatment (see Figures 1–3) and the results, and clinical observation during outpatient contacts indicated no signs of PTSD or depression. He remained pain free for prolonged periods, with a maximum pain of 4.5 at other times. As can be seen in Table 1, at these times, he managed pain by giving himself morphine sulfate if he was in distress.

**Second Hospital Stay (EMDR Sessions 8–11).** Five months following the first hospitalization (despite four previous contacts indicating stable treatment effects), Tom requested additional EMDR treatment because of the reappearance of extended discomfort with his leg and some depressive symptoms. The discomfort would inevitably appear at night, at which time Tom could barely sleep, as the pain level was 8–10. In addition, he was emotionally vulnerable and showed symptoms of depression even after the phantom pain had stopped. In this situation, Tom's need for medications was increased (up to 300 mg morphine sulfate). At readmission, his tests indicated that the scores in the IES and the BDI had increased into the clinical range (see Figures 2 and 3).

To identify the cause of the nighttime distress, Tom was questioned about the circumstances of going to bed in the evening. In response, Tom appeared quite astonished and tried to avoid some details. Asked for the reasons of his defensiveness, he admitted to looking at the photographs of his amputated right leg and his damaged body just before going to bed over the previous 3 weeks. The photographs had been taken upon admission to the hospital and showed his severed leg and injured body. Subsequent to the previous

treatment, Tom had requested the photos to deal with an insurance matter. When he noticed that they upset him, he had established a ritual in an attempt to use these photos to desensitize his distress and "to strengthen himself." However, instead of contributing to recovery, his new "method" had exacerbated his distress.

The next 3 sessions of EMDR focused on these photographs and some of the reports Tom had written for the insurance company that described in gruesome detail his accident and all the complications that had occurred. During each of these sessions, the image of the healthy leg was first used as a strengthening resource before beginning to process his stressful memories (Hofmann, 2002). He called up the image of the healthy leg and the positive body feeling associated with it. Then a slow set of eye movements was initiated. Usually the positive body feeling became stronger, and then another short set of eye movements was applied. Starting from this positive point, the initial memory was targeted, and, for the first time, the full memory of his accident came to consciousness. As this memory passed by like a movie before his inner eye during the processing, he again felt the threat of death and realized that he really could have died. The intensity of these feelings subsided in the session, as did the intensity of his mourning for his wife's miscarriage in the next session. It should be noted that while the positive imagery was used to strengthen Tom at the beginning of the session, the target was accessed without distortion and with full associated affect.

At the end of the second set of EMDR sessions Tom's worst memories and the associated sensations (e.g., the crash, some operations, his first confrontation with his damaged body, and his wife's miscarriage) were comprehensively processed and resolved ecologically, including a realistic perspective on coping with his real disabilities and social handicaps. In the last session, a future perspective was developed where he affirmed that he could have more children and imagined that he could learn to walk again with his one leg and maybe a prosthesis. His thought when he focused on the last image became "I am strong again," and he felt it in his body with a VOC of 6–7.

At discharge from the clinic, Tom had no signs of PTSD, and his IES score was at a subclinical level of 8 (see Figures 2 and 3). Table 1 indicates the session-by-session effects of EMDR processing during the two hospitalizations and the assessments previous to each admission. An examination of the table reveals the correspondence between the 0–10 SUD score indicating the level of distress when Tom is asked to think of the memories attendant to his loss and the parallel decline in his phantom limb pain level as indicated

by the VAS scale. The 3 sessions during the second hospitalization were conducted very close in time, so some data were not collected.

**Follow-Up.** At 1-year follow-up, standardized measures indicated no sign of trauma or depression. At both the 1-year and 18-month follow-ups since his last EMDR session in the spring of 2003, Tom reported no more phantom limb pain. He could control the organic pain in his broken pelvis and rarely needed any related pain medication. Tom's subjective organic pain level, especially when driving his modified motorcycle, was in a range of 2–4. His lack of pain allowed him to walk very skillfully on crutches (a prosthesis was not possible because of anatomical reasons). In spring of 2004, Tom began diving and became a certified rescue diver. In the summer of 2004, he was employed as a diving trainer for disabled travelers.

## Discussion

### Treatment Implications

The usefulness of EMDR has been demonstrated in this severe case of chronic phantom limb pain. Following 3 years of largely unsuccessful treatment efforts, 9 EMDR sessions eliminated Tom's phantom limb pain, significantly reduced previously constant organic pain, and reduced his daily use of morphine sulfate (which was also socially debilitating) from 600 to 100 mg on demand (which he rarely uses). EMDR was also used to address his PTSD and depression symptoms. The patient has renewed his ability to enjoy life and to explore new ways of making use of his time.

Research has indicated that while situational stress may exacerbate the experience of phantom limb pain, the sensation itself should properly be viewed as a physiological event, rather than a psychological one alone (see Sherman, 1997, for a comprehensive review of this literature). The same conclusion can be drawn from research demonstrating cortical reorganization, although it is unclear whether the relationship of such changes to the pain is causal or merely correlational (see Ramachandran & Hirstein, 1998). According to the AIP model, both the emotional components of pain and the pure pain sensations should be conceptualized as memories that have been dysfunctionally stored and that may therefore be processed to resolution.

As noted by Shapiro, this model may help to explain why phantom limb pain can sometimes be prevented by administering epidural agents prior to amputation (e.g., Bach, Noreng, & Tjelliden, 1988) and sometimes not prevented (e.g.,

Elizaga, Smith, Sharar, Edwards, & Hanson, 1994). That is, if the pain is directly related to the experience of surgical amputation, such procedures may effectively reduce subsequent phantom limb pain. However, if the pain is also related to a traumatic injury, prior to the amputation, the epidural procedure will meet with less preventative success since the patient will have a stored somatic memory of the painful injury. Consequently, one might view the traumatic injuries and the amputation as separate potential pain contributors. For instance, in the present case, Tom described the pain in terms of the accident (“it feels like a crushing blow,” and “my leg is torn to pieces”) and in terms that might be related specifically to the amputation, or its residual affects (“dull,” “burning,” and “pressing”).

As seen in Table 1, the pain reports indicated that the initial pain level of 10 began to decrease subsequent to the initiation of processing and continued to do so over the course of treatment, ultimately resulting in a complete elimination, which was maintained at 18-month follow-up. However, it should be noted that the complete cessation of phantom pain was not achieved until the final reprocessing sessions targeted the triggers and associated memories. This observation underscores the need for a comprehensive EMDR regime and follow-up period that addresses the complete clinical picture. As noted in the present case, the initial cessation and subsequent increase in phantom limb pain (which prompted the second treatment sequence) was correlated with the psychological measures of both PTSD and depression (see Figures 1–3). This may imply that the pain sensations contributed to the depression and traumatization. Reciprocally, the added stress may have increased the sensitivity to the pain sensations. Tom reported that the pain had changed and no longer consisted of the sensations of the accident, but resembled a more dull and pressing pain. However, the comprehensive processing afforded by the targeting of the triggers resulted in a complete elimination of the phantom limb pain, as well as the elimination of PTSD and depression symptomatology, which persisted at 1-year and 18-month follow-up. It is also important to note that the phantom pain sensations appear to be correlated with the level of subjective emotional distress that Tom experienced when asked to think of memories associated with his loss (see Table 1). The AIP model posits that the emotions and physical sensations inherent in the unprocessed event and stored inappropriately in memory are the foundation of the current pathology (see Ray & Zbik, 2001; Shapiro, 1995, 2001; Stickgold, 2002).

Also important is the spontaneous emergence of a “healthy leg” when Tom was asked what could help him to feel better. The association of the eye movements with this image resulted in an immediate increase of positive sensations and diminution of pain. Its use as an antidote was also contiguous to the increased duration of pain cessation that was maintained for greater spans of time during the course of the rest of the treatment. This finding has important implications given the present theories and neuroimaging studies reflecting a reorganization of parts of the sensory cortex (e.g., Flor, 2002b). Evaluations of treatments guided by these theories have reported positive effects attained by the use of visuomotor training (Giroux, & Sirigu 2003; Ramachandran, & Rogers-Ramachandran, 1996) to mimic and project an external image of a healthy appendage. The positive treatment effects were reported only after many weeks of daily practice. Therefore, the present finding that a few minutes of eye movements while focused on an internal image of a healthy leg can result in substantial treatment effects is important and deserving of additional research.

This article details the treatment of Tom, who was a participant in the first published study of EMDR treatment of phantom limb pain, conducted with standardized measures and an extensive follow-up (Schneider et al., in press). Furthermore, this is the most complex of the cases of phantom limb pain successfully treated with EMDR by the present authors. Other cases have not necessitated the use of the antidote imagery; the decrease or elimination of the phantom limb pain was achieved with EMDR by processing the pain sensations, etiological events, triggers, and templates associated with the traumatic event, the sense of identity, and potential for a positive future. Other cases of successful treatment with EMDR (Shapiro & Forrest, 1997; Tinker, Wilson, & Becker, 1997; Wilensky, 2000) have also not reported the use of such imagery. However, it may be that the image of a healthy body part may assist client stabilization, increase cortical reorganization, and/or solidify effects with more resistant clients. Parameters for such utility can only be established through future rigorous research. In addition, anecdotal reports indicate that phantom arms may be more resistant to treatment than phantom legs. Perhaps the combined use of such imagery with EMDR would increase treatment efficacy.

The present case study supports EMDR as a potentially important treatment for what has heretofore been considered an essentially intractable pathology. This outcome is especially encouraging given

the dearth of phantom limb pain treatment studies that include long-term follow-up measures, and the fact that those evaluations that did include follow-up tend to report a deterioration or elimination of initial treatment effects (see Sherman, 1997). The remediation of suffering found in Tom’s case supports conjectures that EMDR produces treatment effects for chronic pain patients not previously afforded by other therapies (see Ray & Zbik, 2001). Furthermore, consistent with the AIP model, this outcome indicates that it is possible to eliminate phantom limb pain by EMDR processing of dysfunctionally stored etiological experiences and the resulting issues of self-efficacy and triggers, without the need for additional self-monitoring and continuous reinforcement.

The difference between EMDR outcomes and those of CBT (i.e., cessation versus decrease of pain; see Ray & Zbik, 2001) may potentially be explained by new neurobiological theories on the differences between memory reconsolidation and extinction (Suzuki et al., 2004). According to these theories, treatments that rely on extinction (such as exposure therapies) result in the formation of competing memories, rather than an alteration of the old ones. However, it may prove that EMDR’s effects are based upon a different process known as *reconsolidation* that would involve the change and restorage of the altered targeted memory itself. It has been posited that longer exposures result in extinction, while shorter exposures result in reconsolidation (see Suzuki et al., 2004). Research is needed to explore these possibilities.

Most importantly, the possibility that phantom limb pain can be eliminated or reduced by a brief course of therapy has major implications for clinicians treating patients suffering from this condition. Given that chronic phantom limb pain is relatively widespread in those suffering from traumatic amputations and was previously considered intractable, these findings may also have an important impact on public policy, given the current number of war casualties and accident victims. The research report that included this case (Schneider et al., in press) indicates that 80% of the patients showed a substantial decrease or elimination of phantom pain, which was maintained at 1-year follow up. Similar effects have been reported in other research settings (de Roos & Veenstra, 2005/submitted; Wilensky, submitted). However, large scale randomized studies are needed to identify more precisely what subgroups of phantom limb patients can benefit and to what extent. Rigorous research with long-term follow-up is urged to further explore these treatment parameters.

## Treatment Recommendations

As indicated by Shapiro (2001; Shapiro & Forrest, 1997), the treatment of somatic problems involves not only physical but also psychological and existential issues. It is the “psychological tension or self-identification as a helpless victim that can be the most debilitating factor” (Shapiro, 2001, p. 255). It is important to remember that cases of phantom limb pain may involve not only the possible debilitation caused by the physical sensations but also issues of self-worth, self-efficacy, and unresolved feelings of loss—not only of the limb, but of identity, social status, and an active, positive future. Thus, it is important to note that in the present case the first step of processing the memories of the past not only consisted of processing the accident itself, but additional memories involving fear of impotence, loss, shame, anger at maltreatment, and so forth. These were all necessary for a permanent elimination of the pain. It is vital to take a comprehensive history of the case to explore contributing factors, as they may not always emerge during processing itself. Other targets involving present triggers, and future templates and the material associated with them should address most of the clinical picture.

In some reports of EMDR treatment of pain patients, the possibility is mentioned that another focus of processing could be the present pain itself (Grant, 2002). Although this approach was not used in our phantom limb pain cases (Schneider et al, in press), further research into this targeting approach may be helpful (de Roos & Veenstra, 2005). In our approach, the pain sensations became the focus of treatment as they emerged during the targeting of the initial accident and other specific events. We would suggest that once this is completed, any residual pain sensations should be addressed through a focus on them, along with attention to present triggers. In addition, the pain itself may be focused on as a target if the processing of past, present, and future is not sufficient.

It is also important to include an extensive follow-up in order to identify any new triggers that may elicit previously unresolved elements or cause retraumatization. In this case, the amnesic gaps that Tom suffered may have been compounded by the medication-induced artificial coma. The heavy doses of medication needed to induce the coma directly after the accident may have prevented a full consolidation of the trauma memory, potentially inhibiting comprehensive EMDR processing during the first hospitalization. The lack of generalization to other aspects of the memory may have resulted. In other cases where a coma is induced

subsequent to the accident, it would be useful to investigate the effectiveness of a frame-by-frame targeting of the available memory similar to that used in the recent event protocol (Shapiro, 2001), as well as increased focus on the residual pain sensations themselves, in order to process any memory fragments. In Tom’s case, the photos may have then triggered these unprocessed memories and/or resulted in retraumatization because of the previously unrecalled appearance of his damaged body and severed limb.

Regardless of the apparent complexity or simplicity of the case, it is important to follow the eight phases of EMDR treatment and use the entire three-pronged protocol for the treatment. Only feedback over time can ensure the stability of effects, and clients should be cautioned to report any disturbance or symptoms for further processing. Given the societal and family pressures attendant to readjustment with a permanent physical disability, it is important to ensure at least a 1-year follow-up.

It is interesting to note that the first published case of the cessation of PTSD and pain involving an amputee (McCann, 1992) reported that the client returned to an active and high-functioning life and became an advocate for the disabled, assisting young children to attain prostheses. Likewise, in this case, Tom became a rescue diver and a trainer for disabled travelers. These advocacy roles are representative of a sense of empowerment that includes the desire to protect and assist those in need. When this does not emerge spontaneously, clinicians should explore any perceived barriers to these types of endeavors. It is not unusual for EMDR processing to result in new insights and an enhanced sense of self, with the desire to make the painful experience fruitful and to help others. When the sense of a positive future is lacking, comprehensive treatment is incomplete, and greater attention should be directed to potential targets manifested in the premonitory history (Shapiro, 2001). Ultimately, overt symptom reduction, such as pain elimination, is only one element in the comprehensive clinical picture.

## References

- American Psychiatric Association. (2004). *Practice guideline for the treatment of patients with acute stress disorder and posttraumatic stress disorder*. Arlington, VA: American Psychiatric Association Practice Guidelines.
- Andrade, J., Kavanagh, D., & Baddeley, A. (1997). Eye-movements and visual imagery: A working memory approach to the treatment of post-traumatic stress disorder. *British Journal of Clinical Psychology, 36*, 209–223.

- Bach, S., Noreng, M. F., & Tjelliden, N. U. (1988). Phantom limb pain in amputees during the first 12 months following limb amputation, after preoperative lumbar epidural blockade. *Pain, 33*, 297–301.
- Barrowcliff, A. L., Gray, N. S., Freeman, T. C. A., & MacCulloch, M. J. (2004). Eye-movements reduce the vividness, emotional valence and electrodermal arousal associated with negative autobiographical memories. *Journal of Forensic Psychiatry and Psychology, 15*, 325–345.
- Beck, A. T., Ward, C. G., Mendelssohn, M., Mock, J., & Erbaugh, J. (1961). An inventory for measuring depression. *Archives of General Psychiatry, 4*, 561–571.
- Birbaumer, N., Lutzenberger, W., Montoya, P., & Larbig, W. (1997). Effects of regional anaesthesia on phantom limb pain are mirrored in changes in cortical reorganisation. *Journal of Neuroscience, 17*, 5503–5508.
- Bleich, A., Kotler, M., Kutz, I., & Shalev, A. (2002). *Guidelines for the assessment and professional intervention with terror victims in the hospital and in the community*. Jerusalem, Israel: A position paper of the (Israeli) National Council for Mental Health.
- Bossini, L., Fagiolini, A., & Castrogiovanni, P. (in press). Neuroanatomical changes after EMDR in PTSD. *Journal of Neuropsychiatry and Clinical Neuroscience*.
- Bradley, R., Greene, J., Russ, E., Dutra, L., & Westen, D. (2005). A multidimensional meta-analysis of psychotherapy for PTSD. *American Journal of Psychiatry, 162*, 214–227.
- Brown, K. W., McGoldrick, T., & Buchanan, R. (1997). Body dysmorphic disorder: Seven cases treated with eye movement desensitization and reprocessing. *Behavioural & Cognitive Psychotherapy, 25*, 203–207.
- Carlson, J., Chemtob, C. M., Rusnak, K., Hedlund, N. L., & Muraoka, M. Y. (1998). Eye movement desensitization and reprocessing (EMDR): Treatment for combat-related post-traumatic stress disorder. *Journal of Traumatic Stress, 11*, 3–24.
- Chemtob, C. M., Nakashima, J., & Carlson, J. G. (2002). Brief-treatment for elementary school children with disaster-related PTSD: A field study. *Journal of Clinical Psychology, 58*, 99–112.
- Christman, S. D., Garvey, K. J., Propper, R. E., & Phaneuf, K. A. (2003). Bilateral eye movements enhance the retrieval of episodic memories. *Neuropsychology, 17*, 221–229.
- CREST. (2003). *The management of post traumatic stress disorder in adults*. Belfast: Clinical Resource Efficiency Support Team of the Northern Ireland Department of Health, Social Services and Public Safety.
- de Roos, C., & Veenstra, S. (2005, June). *EMDR and chronic pain*. Paper presented at the 7th EMDR Europe conference, Istanbul, Turkey.
- De Smet, J., Charlton, J. E., & Meynadier, J. (2000). Pain and rehabilitation from land-mine injury. *International Society for the Study of Pain, 111*, 197–202.
- Department of Veterans Affairs & Department of Defense. (2004). *VA/DOD clinical practice guideline for the management of post-traumatic stress*. Washington, DC:.
- Dutch National Steering Committee Guidelines Mental Health Care. (2003). *Multidisciplinary guideline anxiety disorders*. Utrecht, the Netherlands: Quality Institute Health Care CBO/Trimbos Institute.
- Dziegielewska, S., & Wolfe, P. (2000). Eye movement desensitization and reprocessing (EMDR) as a time-limited treatment intervention for body image disturbance and self-esteem: A single subject case study design. *Journal of Psychotherapy in Independent Practice, 1*, 1–16.
- Elizaga, A., Smith, D., Sharar, S., Edwards, T., & Hanson, S. (1994). Continuous regional analgesia by intraneural block: Effect on postoperative opioid requirements and phantom limb pain following amputation. *Journal of Rehabilitation Research and Development, 31*, 179–187.
- Flor, H. (2002a). Phantom pain: Characteristics, causes and treatment. *Lancet Neurology, 1*, 182–189.
- Flor, H. (2002b). The modification of cortical reorganisation and chronic pain by sensory feedback. *Applied Psychophysiology and Biofeedback, 27*, 215–227.
- Flor, H. (2004). Visualisation of phantom limb pain and back pain using imaging techniques—implications for treatment—Visualisierung von Rueckenschmerzen durch Bildgebende Verfahren—Implikationen fuer die Behandlung. *Der Orthopaede, 33*, 553–557.
- Flor, H., Denke, C., Schaefer, M., & Grusser, M. (2001). Sensory discrimination training alters both cortical reorganisation and phantom limb pain. *Lancet, 357*, 1763–1764.
- Giroux, P., & Sirigu, A. (2003). Illusory movements of the paralysed limb restore motor cortex activity. *Neuroimage, 20*, S107–111.
- Grant, M. (1999). *Pain control with EMDR*. Hamden, CT: EMDR Humanitarian Assistance Programs.
- Grant, M., & Threlfo, C. (2002). EMDR in the treatment of chronic pain. *Journal of Clinical Psychology, 58*, 1505–1520.
- Gupta, M., & Gupta, A. (2002). Use of eye movement desensitization and reprocessing (EMDR) in the treatment of dermatologic disorders. *Journal of Cutaneous Medicine and Surgery, 6*, 415–421.
- Halbert, J., Crotty, M., & Cameron, I. D. (2002). Evidence for optimal management of acute and chronic phantom pain: A systematic review. *Clinical Journal of Pain, 18*, 84–92.
- Hautzinger, M., Bailer, M., Worall, H., & Keller, F. (1992). *Beck-Depressions-Inventar*. Bern: Huber Verlag.
- Hofmann, A. (2002). *Absortions technique with EMDR, EMDR-Manual*. Bergisch Gladbach, Germany: EMDR-Institute Germany.
- Horowitz, M. J., Wilmer, N., & Alvarez, W. (1979). Impact of event scale: A measure of subjective stress. *Psychosomatic Medicine, 41*, 209–218.
- INSERM. (2004). *Psychotherapy: An evaluation of three approaches*. Paris: French National Institute of Health and Medical Research.
- Ironson, G. I., Freund, B., Strauss, J. L., & Williams, J. (2002). Comparison of two treatments for traumatic stress: A community-based study of EMDR and prolonged exposure. *Journal of Clinical Psychology, 58*, 113–128.

- Karl, A., Muehlnickel, W., Kurth, R., & Flor, H. (2004). Neuroelectric source imaging of steady state movement related cortical potentials in human upper extremity amputees with and without phantom limb pain. *Pain, 110*, 90–102.
- Kooijman, C. M., Dijkstra, P. U., Geertzen, J. H., Elzinger, A., & van der Shan, C. P. (2000). Phantom pain and phantom sensations in upper limb amputees: An epidemiologic study. *Pain, 87*, 33–41.
- Korn, D. L., & Leeds, A. M. (2002). Preliminary evidence of efficacy for EMDR resource development and installation in the stabilization phase of treatment of complex posttraumatic stress disorder. *Journal of Clinical Psychology, 58*, 1465–87.
- Kuiken, D., Bears, M., Miall, D., & Smith, L. (2001–2002). Eye movement desensitization reprocessing facilitates attentional orienting. *Imagination, Cognition and Personality, 21*(1), 3–20.
- Lamprecht, F., Kohnke, C., Lempa, W., Sack, M., Matzke, M., & Munte, T. (2004). Event-related potentials and EMDR treatment of post-traumatic stress disorder. *Neuroscience Research, 49*, 267–272.
- Lansing, K., Amen, D. G., Hanks, C. & Rudy, L. (in press). High resolution brain SPECT imaging and EMDR in police officers with PTSD. *Journal of Neuropsychiatry and Clinical Neurosciences*.
- Lee, C., Gavriel, H., Drummond, P., Richards, J., & Greenwald, R. (2002). Treatment of post-traumatic stress disorder: A comparison of stress inoculation training with prolonged exposure and eye movement desensitization and reprocessing. *Journal of Clinical Psychology, 58*, 1071–1089.
- Levin, P., Lazrove, S., & van der Kolk, B. A. (1999). What psychological testing and neuroimaging tell us about the treatment of posttraumatic stress disorder (PTSD) by eye movement desensitization and reprocessing (EMDR). *Journal of Anxiety Disorders, 13*, 159–172.
- Lotze, M., Flor, H., Grodd, W., Larbig, W., & Birbaumer, N. (2001). Phantom movements and pain: An fMRI study in upper limb amputees. *Brain, 124*, 2268–2277.
- Marcus, S., Marquis, P., & Sakai, C. (1997). Controlled study of treatment of PTSD using EMDR in an HMO setting. *Psychotherapy, 34*, 307–315.
- Marcus, S., Marquis, P., & Sakai, C. (2004). Three- and 6-month follow-up of EMDR treatment of PTSD in an HMO setting. *International Journal of Stress Management, 11*, 195–208.
- Maxfield, L., & Hyer, L. A. (2002). The relationship between efficacy and methodology in studies investigating EMDR treatment of PTSD. *Journal of Clinical Psychology, 58*, 23–41.
- McCabe, C. S., Haigh, R. C., Ring, E. F. J., Halligan, P. W., Wall, P. D., & Blake, D. R. (2003). A controlled pilot study of the utility of mirror visual feedback in the treatment of complex regional pain syndrome (type 1). *Rheumatology, 42*, 97–101.
- McCann, D. L. (1992). Post-traumatic stress disorder due to devastating burns overcome by a single session of eye movement desensitization. *Journal of Behavior Therapy and Experimental Psychiatry, 23*, 319–323.
- McKechnie, R. (1975). Relief from phantom limb pain by relaxation exercises. *Journal of Behavior Therapy and Experimental Psychiatry, 6*, 262–263.
- Melzack, R. (1992). Phantom limbs. *Scientific American, 226*, 120–126.
- Melzack, R. (1996). Gate control theory: On the evolution of pain concepts. *Pain Forum, 5*, 128–138.
- National Institute for Clinical Excellence. (2005). *Post traumatic stress disorder (PTSD): The management of adults and children in primary and secondary care*. London: NICE Guidelines.
- Oh, D. H., & Choi, J. (2004). Changes in the regional cerebral perfusion after eye movement desensitization and reprocessing: A SPECT study of two cases. *Korean Journal of Biological Psychiatry, 11*, 173–180.
- Power, K. G., McGoldrick, T., Brown, K., Buchanan, R., Sharp, D., Swanson, V., & Karatzias, A. (2002). A controlled comparison of eye movement desensitisation and reprocessing versus exposure plus cognitive restructuring, versus waiting list in the treatment of post-traumatic stress disorder. *Journal of Clinical Psychology and Psychotherapy, 9*, 299–318.
- Price, D. (1999). *Psychological mechanisms of pain and analgesia*. Seattle: IASP Press.
- Ramachandran, V. S., & Hirstein, W. (1998). The perception of phantom limbs. *Brain, 121*, 1603–30.
- Ramachandran, V. S., & Rogers-Ramachandran D. (1996). Synaesthesia in phantom limbs induced with mirrors. *Proceedings of the Royal Society of London B Biological Sciences, 263*, 377–286.
- Ray, A. L., & Zbik, A. (2001). Cognitive behavioral therapies and beyond. In C. D. Tollison, J. R. Satterhwaite, & J. W. Tollison (Eds.), *Practical pain management* (3rd ed., pp. 189–208). Philadelphia: Lippincott.
- Ricci, R. J., Clayton, C. A., & Shapiro, F. (2006). Some effects of EMDR treatment with previously abused child molesters: Theoretical reviews and preliminary findings. *Journal of Forensic Psychiatry and Psychology, 17*, 538–562.
- Rogers, S., & Silver, S. M. (2002). Is EMDR an exposure therapy? A review of trauma protocols. *Journal of Clinical Psychology, 58*, 43–59.
- Rome, H., & Rome J. (2000). Limbically augmented pain syndrome (LAPS): Kindling, cortolimbic sensitization, and convergence of affective and sensory symptoms in chronic pain disorders. *Pain Medicine, 1*, 7–23.
- Rothbaum, B. (1997). A controlled study of eye movement desensitization and reprocessing in the treatment of post-traumatic stress disorder sexual assault victims. *Bulletin of the Menninger Clinic, 61*, 317–334.
- Schneider, J., Hofmann, A., Rost, C., & Shapiro, F. (in press). EMDR in the treatment of chronic phantom limb pain. *Pain Medicine*.

- Shapiro, F. (1989). Efficacy of the eye movement desensitization procedure in the treatment of traumatic memories. *Journal of Traumatic Stress, 2*, 199–223.
- Shapiro, F. (1995). *Eye movement desensitization and reprocessing: Basic principles, protocols and procedures*. New York: Guilford.
- Shapiro, F. (2001). *Eye movement desensitization and reprocessing: Basic principles, protocols and procedures* (2nd ed.). New York: Guilford Press.
- Shapiro, F. (Ed.). (2002). *EMDR as an integrative psychotherapy approach: Experts of diverse orientations explore the paradigm prism*. Washington, DC: American Psychological Association Books.
- Shapiro, F. & Forrest, M. S. (1997). *EMDR*. New York: Basic Books.
- Sherman, R. A. (1997). *Phantom pain*. New York: Plenum Press.
- Sherman, R., Arena, J., Griffin, V., Bruno, G., & Cocilovo, A. (1991). Biofeedback for the treatment of phantom limb pain: An update. *Biofeedback, 7*, 7–8.
- Sherman, R., Ernst, J., Barja, R., & Bruno, G. (1988). Phantom pain: A lesson in the necessity for carrying out careful clinical research in chronic pain problems. *Rehabilitation Research and Development, 25*, vii–x.
- Sherman, R., & Sherman, C. (1985). A comparison of phantom sensations among amputees whose amputations were of civilian and military origins. *Pain, 21*, 91–97.
- Siegel, D. J. (2002). The developing mind and the resolution of trauma: Some ideas about information processing and an interpersonal neurobiology of psychotherapy. In F. Shapiro (Ed.), *EMDR as an integrative psychotherapy approach: Experts of diverse orientations explore the paradigm prism* (pp. 85–122). Washington, DC: American Psychological Association Press.
- Stickgold, R. (2002). EMDR: A putative neurobiological mechanism of action. *Journal of Clinical Psychology, 58*, 61–75.
- Suzuki, A., Josselyn, S. A., Frankland, P. W., Masushige, S., Silva, A. J. & Kida, S. (2004). Memory reconsolidation and extinction have distinct temporal and biochemical signatures. *Journal of Neuroscience, 24*, 4787–4795.
- Tinker, R. H., Wilson, S. A., & Becker, L. (1997, July). *Treatment of phantom limb pain with EMDR*. Paper presented at the annual meeting of the EMDR International Association, San Francisco.
- Tsushima, W. (1982). Treatment of phantom limb pain with EMG and temperature biofeedback. *American Journal of Clinical Biofeedback, 5*, 150–153
- Van den Hout, M., Muris, P., Salemink, E., & Kindt, M. (2001). Autobiographical memories become less vivid and emotional after eye movements. *British Journal of Clinical Psychology, 40*, 121–130.
- Van der Kolk, B., Spinazzola, J., Blaustein, M., Hopper, J., Hopper, E., Korn, D., & Simpson, W. (2007). A randomized clinical trial of EMDR, fluoxetine and pill placebo in the treatment of PTSD: Treatment effects and long-term maintenance. *Journal of Clinical Psychiatry, 68*, 37–46.
- Wain, H. (1986). Pain control with hypnosis in consultation and liaison psychiatry. *Psychiatric Annals, 16*, 106–109.
- Walsh, N., & Walsh, W. (2003). Rehabilitation of landmine victims—the ultimate challenge. *Bulletin of the WHO, 81*, 665–670.
- Wilensky, M. (2000). Phantom limb pain. *EMDRAC Newsletter, 4*, 2–3.
- Wilensky, M. (). *Eye movement desensitization and reprocessing (EMDR) as a treatment for phantom limb pain*. Manuscript submitted for publication.
- Wilson, S., Becker, L. A., & Tinker, R. H. (1995). Eye movement desensitization and reprocessing (EMDR): Treatment for psychologically traumatized individuals. *Journal of Consulting and Clinical Psychology, 63*, 928–937.
- Wilson, S., Becker, L. A., & Tinker, R. H. (1997). Fifteen-month follow-up of eye movement desensitization and reprocessing (EMDR) treatment of post-traumatic stress disorder and psychological trauma. *Journal of Consulting and Clinical Psychology, 65*, 1047–1056.
- Wittchen, H. U., Zaudex, M., & Fydich, T. (1997). [SCID] *SKID-DSM-IV. Strukturiertes Klinisches Interview*. Goettingen, Bern, Toronto: Hogrefe. (Translated from Spitzer R. L., & Williams, J. W. B., (1986), *Structured clinical interview for DSM, PTSD module*, New York: State Psychiatric Institute)
- Wolpe, J. (1958). *Psychotherapy by reciprocal inhibition*. Stanford, CA: Stanford University Press.

Correspondence regarding this article should be directed to Arne Hofmann, EMDR-Institute Germany, Dolmanstrasse 86b, 51427 Bergisch Gladbach, Germany. E-mail: Arne-Hofmann@t-online.de